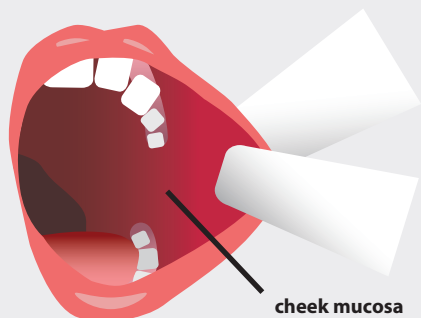

- 1. LOOK**
for white or red spots, a noticeable thickening, or a lump.
- 2. FOLD BACK THE RIGHT, THEN THE LEFT CHEEK**
check in the mirror to see if the mucous membrane is smooth, shiny, pale pink and moist.
- 3. CHECK**
for white or red spots, bumps or wounds.



- 1. LOOK**
for nodules, asymmetry, swelling.
- 2. CHECK BY TOUCH**
prunning your fingers along your neck and under your chin, looking for unusual lumps or tenderness.

ORAL SELF CHECK

Examine your mouth according to the given instructions.

Contact

„Z Uśmiechem Przez Życie” foundation

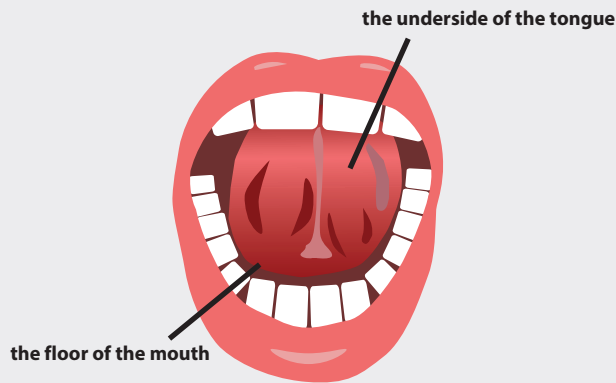
ul. Dzika 2
00-194 Warsaw
tel. +48 22 3517658
e-mail: info@zusmiechem.org.pl,
fundacja@zusmiechem.org.pl



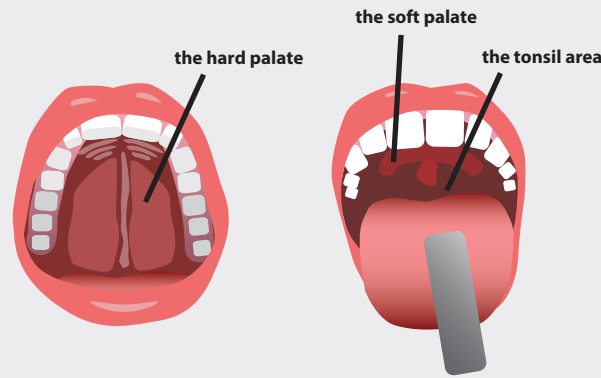
www.zusmiechem.org.pl

KRS: 0000381780
Bank account number: 10 1240 6175 1111 0010 3822 6415
NIP 5242732318
RECON: 142879918

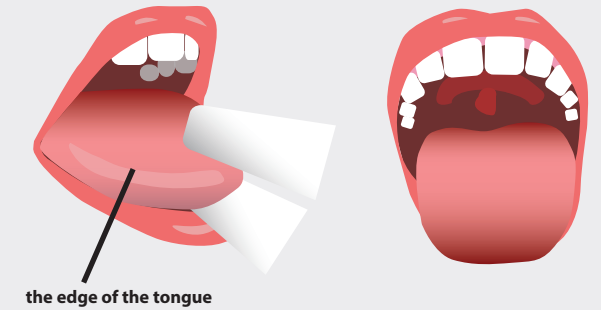




1. **LOOK**
for white or red spots, a noticeable thickening, or a lump.
2. **SLIDE YOUR TONGUE OUT AND LIFT IT UP**
inspecting the underside of your tongue.
3. **CHECK THE BOTTOM OF YOUR MOUTH**
palpating it with your finger, looking for lumps, nodules, and bumps.



1. **LOOK**
for white or red spots, a noticeable thickening, or a lump.
2. **VISUALLY CHECK**
the hard and soft palate, looking for ulcers and white or red spots.
3. **TOUCH**
the palate with your finger, checking for lumps or bumps.



1. **LOOK**
for white or red spots, a noticeable thickening, or a lump.
2. **STICK OUT YOUR TONGUE**
look and check with your finger if its structure is homogeneous.
3. **GRASP THE END OF YOUR TONGUE**
(helping yourself with gauze). Move the tongue to the right, then to the left controlling the appearance and texture of its edges.

Oral self-inspection is fundamental and very important thing when it comes to diagnosing a neoplasm.

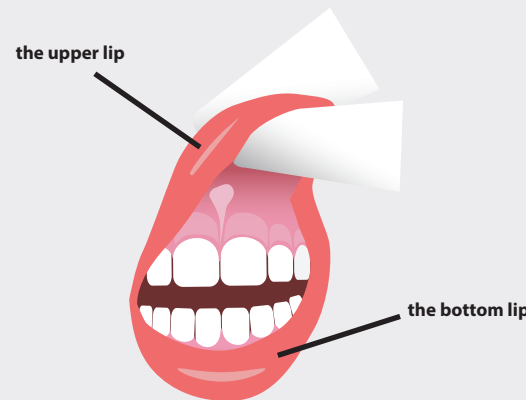
To carry out self-examination, you need a good light, a mirror, a sterile pad (folded sanitary paper, tissue).

Examine your mouth looking for white or red patches, thickening or lump, swelling or asymmetry - normal oral mucosa is smooth, shiny, pale pink and moist.

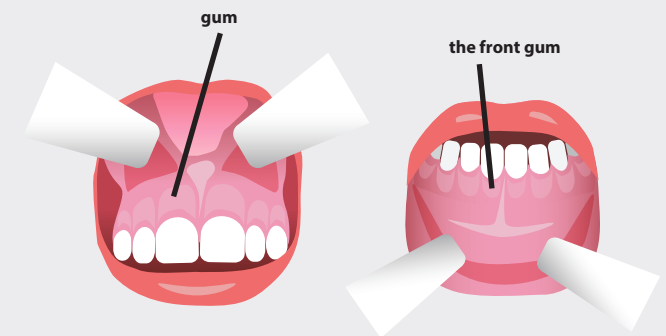
We carry out self-control in two stages:

- by sight
- by touch

If you find a disturbing change that does not go away after 2 weeks, see a doctor (dentist, ENT specialist).



1. **LOOK**
for white or red spots, a noticeable thickening, or a lump.
2. **TILT THE UPPER, THEN THE LOWER LIP**
check the mucosa for a smooth, shiny, pale pink appearance with no disturbing changes.
3. **GRASP THE UPPER, THEN THE LOWER LIP**
check their structure by sliding your fingers along the entire lips.



1. **LOOK**
for white or red spots, a noticeable thickening, or a lump.
2. **CHECK BY TOUCH**
running your fingers over the outside and inside of the gums.